

MORITZ EHLKE, THOMAS FRENZEL, HEIKO RAMM,
HANS LAMECKER, CARSTEN PERKA,
MOHSEN AKBARI SHANDIZ, CAROLYN ANGLIN,
STEFAN ZACHOW

**Robust Measurement
of Natural Acetabular Orientation
from AP Radiographs
using Articulated 3D Shape and
Intensity Models**

Herausgegeben vom
Konrad-Zuse-Zentrum für Informationstechnik Berlin
Takustraße 7
D-14195 Berlin-Dahlem

Telefon: 030-84185-0
Telefax: 030-84185-125

e-mail: bibliothek@zib.de
URL: <http://www.zib.de>

ZIB-Report (Print) ISSN 1438-0064
ZIB-Report (Internet) ISSN 2192-7782

Robust Measurement of Natural Acetabular Orientation from AP Radiographs using Articulated 3D Shape and Intensity Models

Moritz Ehlke^{1,2}, Thomas Frenzel², Heiko Ramm², Hans Lamecker², Carsten Perka³,
Mohsen Akbari Shandiz⁴, Carolyn Anglin⁴, Stefan Zachow²

¹Berlin-Brandenburg School for Regenerative Therapies, ²Medical Planning Group, Zuse Institute Berlin (ZIB), ³Center for Musculoskeletal Surgery, Charité Berlin, ⁴Biomedical Engineering, University of Calgary

Introduction

The orientation of the natural acetabulum is useful for total hip arthroplasty (THA) planning and for researching acetabular problems. Currently the same acetabular component orientation goal is generally applied to all THA patients. Creating a patient-specific plan could improve the clinical outcome. The gold standard for surgical planning is from three-dimensional (3D) computed tomography (CT) imaging. However, this adds time and cost, and exposes the patient to a substantial radiation dose. If the acetabular orientation could be reliably derived from the standard anteroposterior (AP) radiograph, preoperative planning would be more widespread, and research analyses could be applied to retrospective data, after a postoperative issue is discovered. The reduced dimensionality in 2D X-ray images and its perspective distortion, however, lead to ambiguities that render an accurate assessment of the orientation parameters a difficult task. The goal of this work is to enable robust measurement of the acetabular inclination and version on 2D X-rays using computer-aided techniques.

Recently, methods have been proposed to reconstruct the patient-specific 3D pelvic surface and orientation and component orientation from standard 2D *postoperative* X-ray images². We propose a reconstruction method to determine the natural acetabular orientation from a single, *preoperative* X-ray. The approach utilizes novel articulated statistical shape and intensity models (ASSIMs) that express the variance in anatomical shape and bone density of the pelvis/proximal femur between individual patients and model the articulation of the hip joints. In contrast to previous surface-based methods, the ASSIM-based reconstruction approach not only considers the anatomical shape of the pelvis, but also the bone interior density of both the pelvis and proximal femur. The rationale is to use as much information contained in the X-ray as possible, in order to increase the robustness of the 3D reconstruction. The acetabular orientation can then be assessed directly from the reconstructed, patient-specific anatomy model.

Methods

The 3D SSIM of the pelvis described previously¹ was extended to allow a constrained rotation of the proximal femur along three axes. The center of rotation corresponds to the center of a sphere that is fit to the acetabulum, and is embedded in

the statistical analysis of the model³. Deformation parameters allow variations in the anatomical shape, the center of rotation and the bone density distribution of the model while 6 additional articulation parameters are used to express the rotation of the proximal femur relative to the pelvic bone.

The patient-specific 3D pelvis and proximal femur anatomy are reconstructed by means of an iterative process, in which the deformable, articulated model is fit to an X-ray image until the model's 2D projection onto the X-ray plane matches the anatomy depicted in the 2D reference. In each iteration, the ASSIM is deformed, transformed, articulated and a virtual 2D X-ray image generated from the deformed ASSIM instance¹. A mutual-information-based similarity measure is then applied to quantify the similarity between the virtual X-ray and the reference image. Once a suitable match is established, the process returns a tetrahedral grid which approximates the patient-specific anatomical shapes as well as their pose as depicted in the 2D reference image.

In order to obtain the orientation of the acetabulum from the reconstructed model, a total of four landmarks - at the superior iliac spines and pubic tubercles (see Figure 1) - are extracted automatically from the reconstructed grid, utilizing the correspondence between individual vertices of the model's statistical mean shape and the reconstructed instance. These define the anterior pelvic reference plane (APP). The global orientation of the acetabulum is computed from another set of anatomical landmarks located around the acetabular rim. Inclination and version parameters are then obtained from the global orientation by using the APP as the reference plane.

We performed a preliminary evaluation on 6 preoperative AP X-ray and matching CT datasets, for the pelvis and femur of 6 different patients. The patient-specific 3D anatomies were first reconstructed from the 2D images and the inclination and version parameters obtained using the proposed method. These parameters were then compared to gold-standard values assessed independently from the individual patient's CT data.

Results

Average acetabular orientation errors, in absolute values, between the 3D-reconstructed values and the CT gold standard for the right/left hips were 3.86°/2.77° in inclination and 3.73°/4.97° in version. Maximum errors were 8.26°/5.43° in inclination and 6.22°/8.27° in version.

Discussion

We developed a novel, computer-aided reconstruction approach to extract the natural acetabular inclination and anteversion from preoperative 2D AP radiographs. The method considers statistical information about both the 3D bone density distribution and the articulation between the pelvis and proximal femur.

In most cases, the method produced results close to the CT gold standard (e.g. with an error margin of 4°). For the two outliers with an error above 8°, an incorrect fit between the model and reference X-ray was observable in the respective acetabular

region, indicating that the statistical model could not accurately represent the patient-specific anatomy. We believe this is due to the small number of training sets (50) used for the statistical analysis. The accuracy might be enhanced further by expanding the training base of the statistical model. Also, currently the anterior pelvic plane is determined from only 4 points. Using a different plane as reference might increase the robustness when computing the inclination and version parameters.

The proposed approach has added potential since it can be easily extended to reconstruct other important preoperative and postoperative surgical parameters, such as the femoral neck offset, leg length, hip centre and acetabular cup orientation - solely based on a single AP radiograph.

References

[1] Ehlke et al. (2013) Fast generation of virtual X-ray images for reconstruction of 3D anatomy. IEEE TCVG, 19(12): 2673–82. [2] Zheng et al. (2012) Validation of a statistical shape model-based 2D/3D reconstruction method for determination of cup orientation after THA. IJCARS, 7(2): 225–31. [3] Kainmueller et al. (2009) An articulated statistical shape model for accurate hip joint segmentation. IEEE EMB, 6345–51.

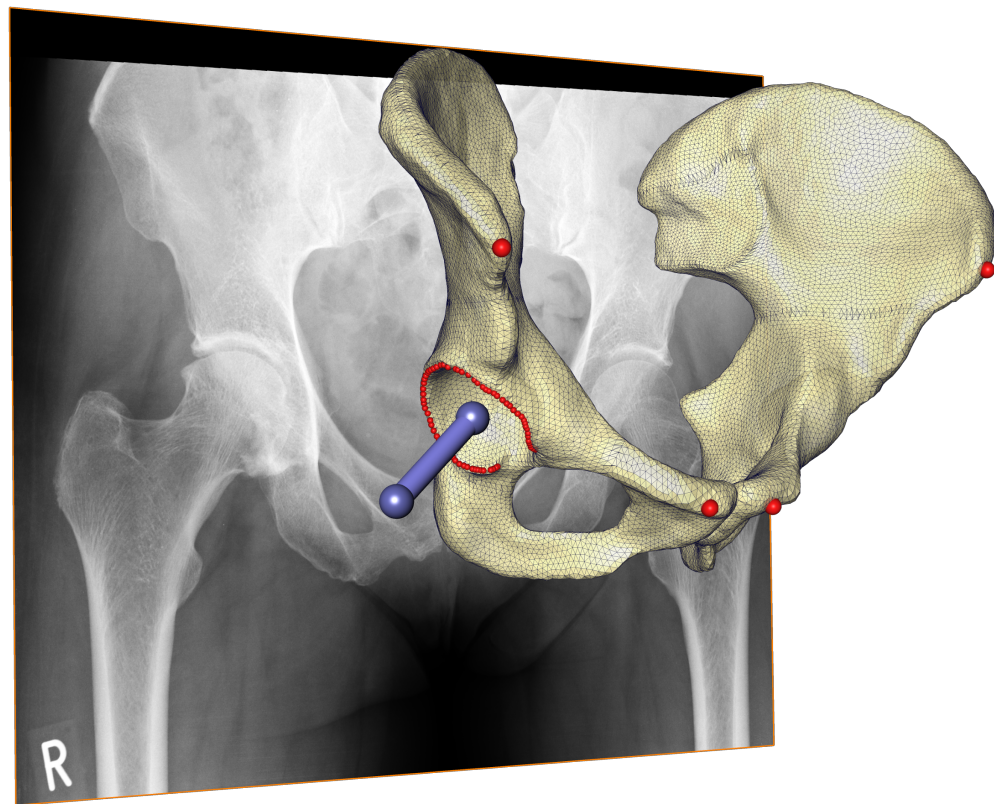


Figure 1: AP radiograph with reconstructed ilia, APP and acetabular reference landmarks (red), and global acetabular orientation vector (blue). Note that the person is standing in front of the X-ray plane, and the projection onto the plane is modeled.