

GEORGIAN MEDICAL NEWS

ISSN 1512-0112

NO 10 (343) Октябрь 2023

ТБИЛИСИ - NEW YORK



ЕЖЕМЕСЯЧНЫЙ НАУЧНЫЙ ЖУРНАЛ

Медицинские новости Грузии
საქართველოს სამედიცინო სიახლენი

GEORGIAN MEDICAL NEWS

Monthly Georgia-US joint scientific journal published both in electronic and paper formats of the Agency of Medical Information of the Georgian Association of Business Press.
Published since 1994. Distributed in NIS, EU and USA.

GMN: Georgian Medical News is peer-reviewed, published monthly journal committed to promoting the science and art of medicine and the betterment of public health, published by the GMN Editorial Board since 1994. GMN carries original scientific articles on medicine, biology and pharmacy, which are of experimental, theoretical and practical character; publishes original research, reviews, commentaries, editorials, essays, medical news, and correspondence in English and Russian.

GMN is indexed in MEDLINE, SCOPUS, PubMed and VINITI Russian Academy of Sciences. The full text content is available through EBSCO databases.

GMN: Медицинские новости Грузии - ежемесячный рецензируемый научный журнал, издаётся Редакционной коллегией с 1994 года на русском и английском языках в целях поддержки медицинской науки и улучшения здравоохранения. В журнале публикуются оригинальные научные статьи в области медицины, биологии и фармации, статьи обзорного характера, научные сообщения, новости медицины и здравоохранения. Журнал индексируется в MEDLINE, отражён в базе данных SCOPUS, PubMed и ВИНТИ РАН. Полнотекстовые статьи журнала доступны через БД EBSCO.

GMN: Georgian Medical News – საქართველოს სამედიცინო სიახლენი – არის ყოველთვიური სამეცნიერო სამედიცინო რეცენზირებადი ჟურნალი, გამოიცემა 1994 წლიდან, წარმოადგენს სარედაქციო კოლეგიისა და აშშ-ის მეცნიერების, განათლების, ინდუსტრიის, ხელოვნებისა და ბუნებისმეტყველების საერთაშორისო აკადემიის ერთობლივ გამოცემას. GMN-ში რუსულ და ინგლისურ ენებზე ქვეყნდება ექსპერიმენტული, თეორიული და პრაქტიკული ხასიათის ორიგინალური სამეცნიერო სტატიები მედიცინის, ბიოლოგიისა და ფარმაციის სფეროში, მიმოხილვითი ხასიათის სტატიები.

ჟურნალი ინდექსირებულია MEDLINE-ის საერთაშორისო სისტემაში, ასახულია SCOPUS-ის, PubMed-ის და ВИНТИ РАН-ის მონაცემთა ბაზებში. სტატიების სრული ტექსტი ხელმისაწვდომია EBSCO-ს მონაცემთა ბაზებშიდან.

WEBSITE

www.geomednews.com

К СВЕДЕНИЮ АВТОРОВ!

При направлении статьи в редакцию необходимо соблюдать следующие правила:

1. Статья должна быть представлена в двух экземплярах, на русском или английском языках, напечатанная через **полтора интервала на одной стороне стандартного листа с шириной левого поля в три сантиметра**. Используемый компьютерный шрифт для текста на русском и английском языках - **Times New Roman (Кириллица)**, для текста на грузинском языке следует использовать **AcadNusx**. Размер шрифта - **12**. К рукописи, напечатанной на компьютере, должен быть приложен CD со статьей.

2. Размер статьи должен быть не менее десяти и не более двадцати страниц машинописи, включая указатель литературы и резюме на английском, русском и грузинском языках.

3. В статье должны быть освещены актуальность данного материала, методы и результаты исследования и их обсуждение.

При представлении в печать научных экспериментальных работ авторы должны указывать вид и количество экспериментальных животных, применявшиеся методы обезболивания и усыпления (в ходе острых опытов).

4. К статье должны быть приложены краткое (на полстраницы) резюме на английском, русском и грузинском языках (включающее следующие разделы: цель исследования, материал и методы, результаты и заключение) и список ключевых слов (key words).

5. Таблицы необходимо представлять в печатной форме. Фотокопии не принимаются. **Все цифровые, итоговые и процентные данные в таблицах должны соответствовать таковым в тексте статьи**. Таблицы и графики должны быть озаглавлены.

6. Фотографии должны быть контрастными, фотокопии с рентгенограмм - в позитивном изображении. Рисунки, чертежи и диаграммы следует озаглавить, пронумеровать и вставить в соответствующее место текста **в tiff формате**.

В подписях к микрофотографиям следует указывать степень увеличения через окуляр или объектив и метод окраски или импрегнации срезов.

7. Фамилии отечественных авторов приводятся в оригинальной транскрипции.

8. При оформлении и направлении статей в журнал МНГ просим авторов соблюдать правила, изложенные в «Единых требованиях к рукописям, представляемым в биомедицинские журналы», принятых Международным комитетом редакторов медицинских журналов - <http://www.spinesurgery.ru/files/publish.pdf> и http://www.nlm.nih.gov/bsd/uniform_requirements.html В конце каждой оригинальной статьи приводится библиографический список. В список литературы включаются все материалы, на которые имеются ссылки в тексте. Список составляется в алфавитном порядке и нумеруется. Литературный источник приводится на языке оригинала. В списке литературы сначала приводятся работы, написанные знаками грузинского алфавита, затем кириллицей и латиницей. Ссылки на цитируемые работы в тексте статьи даются в квадратных скобках в виде номера, соответствующего номеру данной работы в списке литературы. Большинство цитированных источников должны быть за последние 5-7 лет.

9. Для получения права на публикацию статья должна иметь от руководителя работы или учреждения визу и сопроводительное отношение, написанные или напечатанные на бланке и заверенные подписью и печатью.

10. В конце статьи должны быть подписи всех авторов, полностью приведены их фамилии, имена и отчества, указаны служебный и домашний номера телефонов и адреса или иные координаты. Количество авторов (соавторов) не должно превышать пяти человек.

11. Редакция оставляет за собой право сокращать и исправлять статьи. Корректур авторам не высылаются, вся работа и сверка проводится по авторскому оригиналу.

12. Недопустимо направление в редакцию работ, представленных к печати в иных издательствах или опубликованных в других изданиях.

При нарушении указанных правил статьи не рассматриваются.

REQUIREMENTS

Please note, materials submitted to the Editorial Office Staff are supposed to meet the following requirements:

1. Articles must be provided with a double copy, in English or Russian languages and typed or computer-printed on a single side of standard typing paper, with the left margin of 3 centimeters width, and 1.5 spacing between the lines, typeface - **Times New Roman (Cyrillic)**, print size - 12 (referring to Georgian and Russian materials). With computer-printed texts please enclose a CD carrying the same file titled with Latin symbols.

2. Size of the article, including index and resume in English, Russian and Georgian languages must be at least 10 pages and not exceed the limit of 20 pages of typed or computer-printed text.

3. Submitted material must include a coverage of a topical subject, research methods, results, and review.

Authors of the scientific-research works must indicate the number of experimental biological species drawn in, list the employed methods of anesthetization and soporific means used during acute tests.

4. Articles must have a short (half page) abstract in English, Russian and Georgian (including the following sections: aim of study, material and methods, results and conclusions) and a list of key words.

5. Tables must be presented in an original typed or computer-printed form, instead of a photocopied version. **Numbers, totals, percentile data on the tables must coincide with those in the texts of the articles.** Tables and graphs must be headed.

6. Photographs are required to be contrasted and must be submitted with doubles. Please number each photograph with a pencil on its back, indicate author's name, title of the article (short version), and mark out its top and bottom parts. Drawings must be accurate, drafts and diagrams drawn in Indian ink (or black ink). Photocopies of the X-ray photographs must be presented in a positive image in **tiff format**.

Accurately numbered subtitles for each illustration must be listed on a separate sheet of paper. In the subtitles for the microphotographs please indicate the ocular and objective lens magnification power, method of coloring or impregnation of the microscopic sections (preparations).

7. Please indicate last names, first and middle initials of the native authors, present names and initials of the foreign authors in the transcription of the original language, enclose in parenthesis corresponding number under which the author is listed in the reference materials.

8. Please follow guidance offered to authors by The International Committee of Medical Journal Editors guidance in its Uniform Requirements for Manuscripts Submitted to Biomedical Journals publication available online at: http://www.nlm.nih.gov/bsd/uniform_requirements.html
http://www.icmje.org/urm_full.pdf

In GMN style for each work cited in the text, a bibliographic reference is given, and this is located at the end of the article under the title "References". All references cited in the text must be listed. The list of references should be arranged alphabetically and then numbered. References are numbered in the text [numbers in square brackets] and in the reference list and numbers are repeated throughout the text as needed. The bibliographic description is given in the language of publication (citations in Georgian script are followed by Cyrillic and Latin).

9. To obtain the rights of publication articles must be accompanied by a visa from the project instructor or the establishment, where the work has been performed, and a reference letter, both written or typed on a special signed form, certified by a stamp or a seal.

10. Articles must be signed by all of the authors at the end, and they must be provided with a list of full names, office and home phone numbers and addresses or other non-office locations where the authors could be reached. The number of the authors (co-authors) must not exceed the limit of 5 people.

11. Editorial Staff reserves the rights to cut down in size and correct the articles. Proof-sheets are not sent out to the authors. The entire editorial and collation work is performed according to the author's original text.

12. Sending in the works that have already been assigned to the press by other Editorial Staffs or have been printed by other publishers is not permissible.

**Articles that Fail to Meet the Aforementioned
Requirements are not Assigned to be Reviewed.**

ავტორთა საქურაღებოლ!

რედაქციაში სტატიის წარმოდგენისას საჭიროა დაიცვათ შემდეგი წესები:

1. სტატია უნდა წარმოადგინოთ 2 ცალად, რუსულ ან ინგლისურ ენებზე დაბეჭდილი სტანდარტული ფურცლის 1 გვერდზე, 3 სმ სიგანის მარცხენა ველისა და სტრიქონებს შორის 1,5 ინტერვალის დაცვით. გამოყენებული კომპიუტერული შრიფტი რუსულ და ინგლისურენოვან ტექსტებში - **Times New Roman (Кириллица)**, ხოლო ქართულენოვან ტექსტში საჭიროა გამოვიყენოთ **AcadNusx**. შრიფტის ზომა – 12. სტატიას თან უნდა ახლდეს CD სტატიით.

2. სტატიის მოცულობა არ უნდა შეადგენდეს 10 გვერდზე ნაკლებს და 20 გვერდზე მეტს ლიტერატურის სიის და რეზიუმეების (ინგლისურ, რუსულ და ქართულ ენებზე) ჩათვლით.

3. სტატიაში საჭიროა გაშუქდეს: საკითხის აქტუალობა; კვლევის მიზანი; საკვლევი მასალა და გამოყენებული მეთოდები; მიღებული შედეგები და მათი განსჯა. ექსპერიმენტული ხასიათის სტატიების წარმოდგენისას ავტორებმა უნდა მიუთითონ საექსპერიმენტო ცხოველების სახეობა და რაოდენობა; გაუტკივარებისა და დაძინების მეთოდები (მწვავე ცდების პირობებში).

4. სტატიას თან უნდა ახლდეს რეზიუმე ინგლისურ, რუსულ და ქართულ ენებზე არანაკლებ ნახევარი გვერდის მოცულობისა (სათაურის, ავტორების, დაწესებულების მითითებით და უნდა შეიცავდეს შემდეგ განყოფილებებს: მიზანი, მასალა და მეთოდები, შედეგები და დასკვნები; ტექსტუალური ნაწილი არ უნდა იყოს 15 სტრიქონზე ნაკლები) და საკვანძო სიტყვების ჩამონათვალი (key words).

5. ცხრილები საჭიროა წარმოადგინოთ ნაბეჭდი სახით. ყველა ციფრული, შემაჯამებელი და პროცენტული მონაცემები უნდა შეესაბამებოდეს ტექსტში მოყვანილს.

6. ფოტოსურათები უნდა იყოს კონტრასტული; სურათები, ნახაზები, დიაგრამები - დასათაურებული, დანომრილი და სათანადო ადგილას ჩასმული. რენტგენოგრამების ფოტოასლები წარმოადგინეთ პოზიტიური გამოსახულებით **tiff** ფორმატში. მიკროფოტოსურათების წარწერებში საჭიროა მიუთითოთ ოკულარის ან ობიექტივის საშუალებით გადიდების ხარისხი, ანათალებების შედეგების ან იმპრეგნაციის მეთოდი და აღნიშნოთ სურათის ზედა და ქვედა ნაწილები.

7. სამამულო ავტორების გვარები სტატიაში აღინიშნება ინიციალების თანდართვით, უცხოურისა – უცხოური ტრანსკრიპციით.

8. სტატიას თან უნდა ახლდეს ავტორის მიერ გამოყენებული სამამულო და უცხოური შრომების ბიბლიოგრაფიული სია (ბოლო 5-8 წლის სიღრმით). ანბანური წყობით წარმოდგენილ ბიბლიოგრაფიულ სიაში მიუთითეთ ჯერ სამამულო, შემდეგ უცხოელი ავტორები (გვარი, ინიციალები, სტატიის სათაური, ჟურნალის დასახელება, გამოცემის ადგილი, წელი, ჟურნალის №, პირველი და ბოლო გვერდები). მონოგრაფიის შემთხვევაში მიუთითეთ გამოცემის წელი, ადგილი და გვერდების საერთო რაოდენობა. ტექსტში კვადრატულ ფხიხლებში უნდა მიუთითოთ ავტორის შესაბამისი N ლიტერატურის სიის მიხედვით. მიზანშეწონილია, რომ ციტირებული წყაროების უმეტესი ნაწილი იყოს 5-6 წლის სიღრმის.

9. სტატიას თან უნდა ახლდეს: ა) დაწესებულების ან სამეცნიერო ხელმძღვანელის წარდგინება, დამოწმებული ხელმოწერითა და ბეჭდით; ბ) დარგის სპეციალისტის დამოწმებული რეცენზია, რომელშიც მითითებული იქნება საკითხის აქტუალობა, მასალის საკმაობა, მეთოდის სანდოობა, შედეგების სამეცნიერო-პრაქტიკული მნიშვნელობა.

10. სტატიის ბოლოს საჭიროა ყველა ავტორის ხელმოწერა, რომელთა რაოდენობა არ უნდა აღემატებოდეს 5-ს.

11. რედაქცია იტოვებს უფლებას შეასწოროს სტატია. ტექსტზე მუშაობა და შეჯერება ხდება საავტორო ორიგინალის მიხედვით.

12. დაუშვებელია რედაქციაში ისეთი სტატიის წარდგენა, რომელიც დასაბეჭდად წარდგენილი იყო სხვა რედაქციაში ან გამოქვეყნებული იყო სხვა გამოცემებში.

აღნიშნული წესების დარღვევის შემთხვევაში სტატიები არ განიხილება.

Martirosyan T.R. ON THE RESULTS OF A SYSTEMIC MULTIFACTOR ANALYSIS WITH MATHEMATICAL MODELING OF THE INDICATORS OF MEDICAL EXPERTISE OF YOUNG MALES WITH SURGICAL DISEASES IN THE REPUBLIC OF ARMENIA.....	6-13
Hussam S. Ahmed, Nihad N. Hilal, Mohamed G. Zakari. EVALUATION OF VITAMIN K2 IN PATIENTS WITH TYPE 2 DIABETES MELLITUS.....	14-17
Denis Shiyan, Olga Trach, Liliia Sosonna, Nadiia Yurevych, Ganna Chekhovska, Denys Malieiev, Victoriia Alekseeva, Vitaliy Gargin. PEDAGOGICAL ASPECTS OF THE IMPACT OF SMOKING ON THE HUMAN BODY BASED ON RADIOGRAPHIC DENSITY INDICATORS OF MAXILLARY SINUS BONE WALLS.....	18-22
Tereza Azatyan. THE RHEOENCEPHALOGRAPHIC STUDY OF THE INTERHEMISPHERIC ASYMMETRY OF CEREBRAL BLOOD FLOW IN HEALTHY AND MENTALLY RETARDED CHILDREN.....	23-27
Asmaa Y Thanoon, Faehaa Azher Al-Mashhadane. RELATIONSHIP BETWEEN VITAMIN D DEFICIENCY AND CHRONIC PERIODONTITIS.....	28-32
Maia Ispireli, Irma Buchukuri, Tamar Ebanoidze, Giorgi Durglishvili, Nato Durglishvili, Nana Chkhikvishvili, Leila Beridze. CORRELATES OF ATOPIC DERMATITIS CHARACTERISTICS IN MILITARY PERSONNEL.....	33-37
Suhas Ballal, Amandeep Singh, Nimisha Jain, Harsh Bhati, Salahuddin, Devanshu J. Patel. AN IN-DEPTH ASSESSMENT OF THE TUMOR'S IMPACT ON SARCOPENIA.....	38-43
Lilia Robert Mirzoyan, Nara Azat Mkrtchyan, Sergey Nikolay Simonov, Zinaida Tital Indoyan. ASSESSMENT OF THE QUALITY OF LIFE AND PREVALENCE OF POSSIBLE OSTEOPOROTIC CHANGES IN POSTMENOPAUSAL WOMEN IN YEREVAN BASED ON DATA OF THE ECOS-16 QUESTIONNAIRE.....	44-49
Alexander Schuh, Inge Unterpainner, Stefan Sesselmann, Matthias Feyrer, Philipp Koehl. CUBITAL TUNNEL SYNDROME DUE TO AN INTRANEURAL GANGLION CYST OF THE ULNAR NERVE.....	50-52
Ahmed Mohammed Ibrahim, Bashar Sh. Mustafa, Fahad A. Jameel. PREDICTION OF IRON DEFICIENCY IN CHILDREN USING EASY LABORATORY TOOLS.....	53-56
Sharadze D. Z, Abramov A. Yu, Konovalov O.E, Fomina A.V, Generalova Yu.A, Kakabadze E. M, Bokova E. A, Mityushkina T.A, Korovushkina E.K, Kozlova Z.V, Eliseeva T.A. THE OCCURRENCE OF SPORTS INJURIES AMONG PRE-ADOLESCENTS.....	57-62
Balasis J. mahmmoed, Nihad N. Hilal, Entedhar R. Sarhat. EVALUATION OF FETUIN-A LEVEL IN POLYCYSTIC OVARY SYNDROME AND ITS ASSOCIATION WITH ASPROSIN AND SOME BIOCHEMICALPARAMETERS.....	63-66
Boldyreva Yu.V, Lebedev I.A, Zakharchuk E.V, Shhepankevich L.A, Tersenov A.O. THERAPEUTIC USE OF RESVERATROL IN THE TREATMENT OF NEUROLOGICAL AND ENDOCRINOLOGICAL PATIENTS.....	67-70
Suhas Ballal, Nabeel Ahmad, Anand Mohan Jha, Vasundhara Sharma, Rakhi Mishra, Geetika M. Patel. AN EVALUATION OF ANTIBIOTIC PRESCRIPTION PRACTICES: PERSPECTIVES OF VETERINARY TRAINEES AND PRACTICING VETERINARIANS.....	71-77
Elguja Ardia, Tamaz Gvenetadze, Teimuraz Gorgodze, Emzar Diasamidze. CHANGES IN SPERMATOGENESIS AFTER SIMULATED INGUINAL HERNIA REPAIR IN EXPERIMENT.....	78-83
Ioseb Begashvili, Merab Kiladze, George Grigolia. EFFECT OF INHALED OXYGEN CONCENTRATION ON PULMONARY GAS EXCHANGE DURING OFF-PUMP CORONARY BYPASSGRAFTING.....	84-90
Saif Aldeen Alkakaee, Jawnaa Khalid Mamdoh. COQ10 PROVIDES CARDIOPROTECTION AGAINST THE TOXIC EFFECTS OF TRASTUZUMAB AND DOXORUBICIN IN RAT MODEL.....	91-97
Geetika M. Patel, Upendra Sharma.U.S, Bhupendra Kumar, Pankti Patel, Ashish Chander, Pankaj Kumar Tyagi. UNDERSTANDING THE VITAL DETERMINANTS SHAPING LEARNERS' PHYSICAL ACTIVITYAND PSYCHOEMOTIONAL WELLBEING IN THE COVID-19 PERIOD.....	98-103
Matthias Feyrer, Alexander Schuh, Holger Rupprecht, Harald Hennig, Stefan Sesselmann, Philipp Koehl. TRAUMATIC PULMONARY HERNIATION: A RARE CHEST TRAUMA MANIFESTATION.....	104-106
Sami A. Zbaar, Sawsan S. Hosi, Doaa Sabeeh Al-Nuaimi. ASSOCIATION OF NESFATIN-1 AND INSULIN RESISTANCE IN OBESE ADOLESCENTS OF IRAQI POPULATION.....	107-110
Hassan A. Saad, Mohamed E. Eraky, Ahmed K El-Tahe, Mohamed Riad, Khaled Sharaf, Azza Baz, Mohamed I. Farid, Ahmed Salah Arafa. A THOROUGH STUDY AND META-ANALYSIS OF THE PROGNOSTIC RELEVANCE OF THE C-REACTIVE-ALBUMIN RATIO IN ACUTEPANCREATITIS.....	111-118

Shoko Nishikawa, Takuma Hayashi, Tohko Uzaki, Nobuo Yaegashi, Kaoru Abiko, Ikuo Konishi. POTENTIAL LIFE PROGNOSTIC MARKER FOR MESENCHYMAL TUMOR RESEMBLING UTERINE LEIOMYOSARCOMA...	119-126
Lytvynenko M.V, Antonenko P.B, Lobashova K.G, Kashchenko O.A, Bondarenko A.V, Bondarenko O.V, Gargin V.V. PECULIARITIES OF IMMUNE STATUS IN THE PRESENCE OF SECONDARY IMMUNODEFICIENCY OF INFECTIOUS AND NON- INFECTIOUS ORIGIN IN WOMEN OF REPRODUCTIVE AGE.....	127-133
Devanshu J. Patel, Uzma Noor Shah, Nabeel Ahmad, Rajnish Garhwal, Sudhir Singh, Arvind Kumar. UNDERSTANDING THE ADAPTATION AND SENSITIVITY OF THE MICROBIOME: MICROBIAL RESILIENT AND HUMAN WELL- BEING.....	134-138
Sarkulova Zh.N, Tokshilykova A.B, Sarkulov M.N, Daniyarova K.R, Kalieva B.M, Tleuova A.S, Satenov Zh.K, Zhankulov M.H, Zhienalina R.N. FACTORS OF AGGRESSION AT THE STAGES OF OPEN SURGICAL TREATMENT OF SEVERE FORMS OF PERITONITIS.....	139-143
Anamika Tiwari, Geetika M. Patel, Nayana Borah, Amandeep Singh, Shabir Ahmad Shah, Anish Prabhakar. COVID-19 SAFETY MEASURES AND THEIR EFFECTS ON GAMBLING HABITS: AN INVESTIGATIVE STUDY.....	144-152
Mohammed.A.Alghamdi, Rajab Alzahrani, Abdullah Alghamdi, Mujtaba A.Ali, Amal M.Alghamdi, Waad M.Alghamdi, Kholoud M.Alghamdi, Shroog M Alghamdi. AWARENESS AND KNOWLEDGE OF OBSTRUCTIVE SLEEP APNEA AMONG THE POPULATION OF THE AL-BAHA REGION OF SAUDI ARABIA: A CROSS-SECTIONAL STUDY.....	153-158
Khoroshukha M, Bosenko A, Nevedomsjka J, Omeri I, Tymchyk O. INFLUENCE OF SEROLOGICAL MARKERS OF BLOOD GROUPS ON THE DEVELOPMENT OF VISUAL MEMORY FUNCTION IN YOUNG FEMALE ATHLETES AGED 13-15 YEARS.....	159-164
Kavina Ganapathy, Bhupendra Kumar, Shubham Shekhawat, Soubhagya Mishra, Rashmi Mishra, Devanshu J. Patel. EXPLORING CLINICAL VARIATIONS AND CO-MORBID TRENDS IN PD-MCI GROUPS.....	165-171
Georgi Tchernev. METASTATIC NODULAR MELANOMA DEVELOPING ON NEVUS SPILUS DURING INTAKE OF BETA BLOCKERS (BISOPROLOL/ NEBIVOLOL) AND ACE INHIBITORS (PERINDOPRIL). POTENTIAL LINKS TO THE DRUG RELATED NITROSOGENESIS/CARCINOGENESIS, DUNNING-KRUGER EFFECT AND GENETIC WEAPONS OF THE NEW GENERATION.....	172-178
Sanjeev Kumar Jain, Swarupanjali Padhi, Geetika M. Patel, Malathi.H, Bhupendra Kumar, Shweta Madaan. AN INCREASED RISK OF HORMONAL DISORDERS, PRIMARILY DIABETES, IN INDIVIDUALS WITH β -THALASSEMIA MAJOR: A RETROSPECTIVE ANALYSIS.....	179-185
Garima Jain, Komal Patel, Uzma Noor Shah, Minnu Sasi, Sanjana Sarna, Sudhir Singh. INNOVATIONS IN FOCUS: MECHANISTIC DISEASE THEORIES, CLIMATE DYNAMICS, AND HOST-PARASITE ADAPTATIONS.....	186-192
Sharadze D. Z, Abramov A. Yu, Konovalov O.E, Fomina A.V, Generalova Yu.A, Kakabadze E. M, Bokova E. A, Eliseeva T.A, Kostinskaya M.V, Smirnov D.P, Urazgulov A.K. THE INCIDENCE OF SPORTS INJURIES AMONG SCHOOL-AGED CHILDREN AND ADOLESCENTS.....	193-198
Raman Batra, Devanshu J. Patel, Asha.K, Amandeep Singh, Shivam Bhardwaj, Prerana Gupta. EXPLORING MEDICAL STUDENTS' COMPETENCY IN UNDERSTANDING PRIMARY IMMUNODEFICIENCY DISEASES IN INDIA.....	199-203
Matthias Feyrer, Stefan Sesselmann, Philipp Koehl, Alexander Schuh. AN INTRATENDINOUS GANGLION CYST OF THE PATELLAR TENDON: A RARE CAUSE OF ANTERIOR KNEE PAIN.....	204-205

CUBITAL TUNNEL SYNDROME DUE TO AN INTRANEURAL GANGLION CYST OF THE ULNAR NERVE

Alexander Schuh¹, Inge Unterpaintner², Stefan Sesselmann^{3*}, Matthias Feyrer⁴, Philipp KoehP².

¹Hospital of trauma surgery, Department of musculoskeletal research, Marktrechwitz Hospital, 95615 Marktrechwitz, Germany.

²Hospital of trauma surgery, Marktrechwitz Hospital, 95615 Marktrechwitz, Germany.

³Technical University of Applied Sciences Würzburg-Schweinfurt, 97070 Würzburg, Germany.

⁴Department of Industrial Engineering and Health, Institute of Medical Engineering, Technical University of Applied Sciences Amberg-Weiden, 92637 Weiden, Germany.

Abstract.

Cubital tunnel syndrome is the second most common neuropathy of the upper extremity. Cubital tunnel syndrome caused by intraneural ganglion cysts is rare in clinical practice.

We present the case of a 71-year-old male patient with a 4-month history of cubital tunnel syndrome of the left elbow due to an intraneural ganglion cyst. After revision of the ulnar nerve and resection of the intraneural cyst nearly complete recovery was achieved within a 5 month follow-up but some sensory deficits of the fifth fingertip. We recommend preoperative ultrasound examination of the cubital tunnel even in cases with clear diagnosis. Ganglion cyst as a cause of cubital tunnel is rare but needs to be diagnosed and treated as soon as possible to prevent irreversible complications.

Key words. Intraneural, Cubital tunnel syndrome, Ganglion, Cyst, ulnar nerve.

Introduction.

Cubital tunnel syndrome is the second most common neuropathy of the upper extremity. There is usually no obviously detectable preoperative cause, and it is considered primary and related to altered anatomy of the tunnel elements, subluxation of the nerve, or stretching of the nerve by bad habits [1-9]. Potential ulnar nerve entrapment can occur at five sites around the elbow: the arcade of Struthers, the medial intermuscular septum, the medial epicondyle, the cubital tunnel (most common), and the deep flexor pronator aponeurosis [7]. Cubital tunnel syndrome caused by intraneural or perineural ganglion cysts is rare in clinical practice. Elbow ganglion cysts are the third most common causative factor associated with cubital tunnel syndrome. The estimated prevalence rate of these cysts is up to 8% in these patients [8]. However, reports focusing on cubital tunnel syndrome patients with ganglion cysts are still few [1-9].

We present the case of a 71-year-old male patient with a 4-month history of cubital tunnel syndrome of the left elbow due to an intraneural ganglion cyst.

Case report.

A 71-year-old man was suffering from progredient cubital tunnel syndrome of the left elbow with increasing weakness, pain, and numbness of the 1½ ulnar fingers of the left hand. Duration of the progredient symptoms was 4 months. There was no history of trauma. Past medical history was negative for a significant finding.

On clinical examination, tenderness was observed in the left elbow at the medial aspect, Tinel's and Froment's signs were

positive. The elbow flexion test was positive, too. There was no axial deviation of the left elbow, there was no lack in ROM of the left elbow.

Neurologic examination revealed severe weakness of the flexor digitorum profundus of the fourth and fifth fingers (grade 2-3/5), numbness of the 1½ ulnar fingers and severe atrophy of intrinsic muscles of the left hand.

Electrophysiologic study demonstrated delayed conduction of the ulnar nerve at the elbow with severe degree of denervation of ulnar-innervated muscle groups due to a severe cubital syndrome.

Diagnosis of cubital tunnel syndrome was made, we recommended release of the ulnar nerve at the site of cubital tunnel.

After incising 12cm along the cubital tunnel via a posteromedial approach an intraneural cyst was observed in the ulnar nerve (Figure 1a). There were no osteophytes within the cubital tunnel. Additionally the ulnar nerve was revised at the arcade of Struthers, intermuscular septum, Osbourne's ligament, two heads of flexor carpi ulnaris, and deep flexor pronator aponeurosis, whereas there was no compression of the ulnar nerve detected. Figure 1b shows intraoperative situs after resection of the intraneural cyst.

Histopathologic evaluation of the sample of the cysts confirmed the diagnosis of an intraneural ganglion cyst.

At latest follow-up after five months the patient was out of complaints and very satisfied. Complete motoric recovery without any functional limitations was achieved. The patient was out of any pain, there were just some sensory deficitis of the 5th fingertip left.

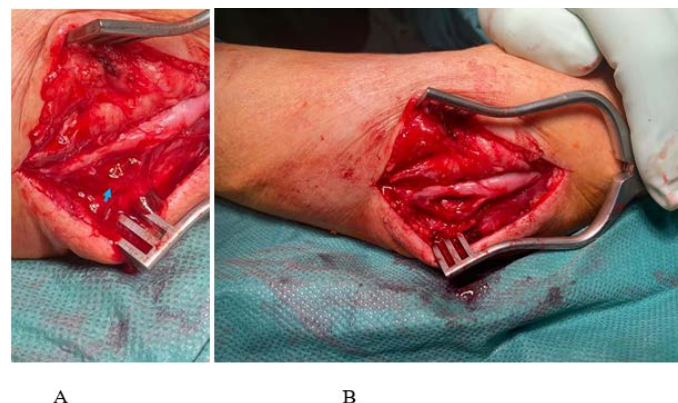


Figure 1. A: Revision of the left cubital tunnel revealed an intraneural ganglion cyst (blue arrow).

B: Intraoperative situs after resection of the ganglion cyst.

Discussion.

The ulnar nerve originates from the C7, C8, and T1 nerve roots. After the formation in the medial cord, it traverses medial to the axillary artery. Later it pierces the medial intermuscular septum and lies in the posterior compartment where it passes through the cubital tunnel. The cubital tunnel is between the medial epicondyle and olecranon and is bounded posteriorly by Osborne's ligament and rarely by the anconeus epitrochlearis muscle. Flexion of the elbow can cause compression of ulnar nerve in the cubital tunnel [9]. Smoking, recurrent subluxation, and male gender are at high risk for cubital tunnel syndrome [9]. Patients suffering from cubital tunnel syndrome usually present with compression symptoms such as pain, numbness, and loss of normal hand movements. Advanced stages of this syndrome lead to irreversible muscle atrophy and contracture of the hand (clawing). Symptoms can be relieved by ulnar nerve decompression, which prevents progression into advanced stages of dysfunction [1]. Intra-neural ganglionic cysts are rarely found to be causative of cubital tunnel syndrome. Ganglion cysts are benign mucinous lesions that typically occur near joints and may affect neighboring nerves by their location and size [6,8]. However, most of the studies regarding development of neural cysts around the ulnar nerve at the cubital tunnel have described cases of epineural cysts, while intra-neural cysts are much less commonly reported with only few studies describing these lesions [5]. The pathogenesis of intra-neural ganglion cysts remains unclear [4].

Three different theories have been proposed for the development of these lesions: the degenerative theory, the tumoral theory and the synovial articular theory. According to the degenerative theory, a certain degree of degeneration of the surrounding neural sheaths (i.e., epineurium, perineurium) results in mucus formation which is subsequently walled off by these sheaths and forms cysts along the nerve [5,6,7]. The tumoral theory, which is the least favoured, speculates that these cysts are similar to other cystic lesions and neural tumors while the synovial theory is constantly gaining ground [5]. A connection of the joint with the parent nerve through an articular branch is responsible for the formation of the cysts [5].

In the upper extremity, ganglion cysts occur most frequently in the ulnar nerve and may be intra-neural or extra-neural in location. According to a recent systematic review, neural cysts around the elbow comprise only 9% all cases [8]. The recurrence rate is 11% following primary surgery involving only resection of the cyst (s) [1]. Our patient did not have a palpable mass along the medial side of elbow. We did not perform a (magnetic resonance imaging) MRI or an ultrasonography (US) preoperatively after final diagnosis of a cubital tunnel syndrome.

The definitive diagnostic modality for such cysts is MRI or US. Cubital tunnel syndrome is a common pathology, therefore, using such methods of diagnosis is neither routinely done nor cost-effective when the etiology is clear [1]. In the diagnosis of intra-neural ganglion cysts, high-resolution MRI is essential for diagnosis and morphologic classification of intra-neural ganglion cysts. Two imaging signs, the signet ring and the transverse limb signs have been suggested to be extremely

robust in differential diagnosis of intra-neural ganglion cysts and more common extra-neural variants [6].

Neural cysts may displace nerve fascicles and cause compressive neuropathy leading to neural entrapment syndromes such as cubital tunnel syndrome. In several cases, they may pose a differential diagnosis problem, since they can masquerade as nerve sheath tumors or other mass occupying lesions [5].

Ganglion cyst as a cause of cubital tunnel is rare but needs to be diagnosed and treated as soon as possible to prevent irreversible complications [3].

We follow Papadopoulos et al. [5] that surgical management of ulnar nerve neural cysts in cubital tunnel should follow the same principles applied in all cases of cubital tunnel syndrome and in any case of neural cysts. Exploration and decompression of the nerve at every possible site of compression along its course in cubital tunnel should be performed, while cysts must be addressed accordingly. In contrast to Tong et al. [7] we believe that decompression of the nerve and resection of the cyst is the optimal surgical procedure [5]. Tong et al. showed that additional subcutaneous transposition of the nerve following drainage of the cysts and ligation of the connecting articular branch yield excellent results [7].

Early diagnosis and surgical treatment are essential for the postoperative recovery of patients with cubital tunnel syndrome due to intra-neural cyst [8].

Conclusion.

Cubital tunnel syndrome due to an intra-neural ganglion cyst of the ulnar nerve is a rare condition but should be kept in mind. We recommend preoperative US of the cubital tunnel even in cases with clear diagnosis.

REFERENCES

1. Alsaygh EF, Abduh WK, Alshahir AA. Cubital Tunnel Syndrome Due to Multiple Intra-neural Cysts at Elbow: A Case Report and Review of Literature. *Cureus*. 2023;15:e36449.
2. Chang WK, Li YP, Zhang DF, et al. The cubital tunnel syndrome caused by the intra-neural or extra-neural ganglion cysts: Case report and review of the literature. *J Plast Reconstr Aesthet Surg*. 2017;70:1404-1408.
3. Farzan M, Abdoli A, Sadeghian M, et al. Painful Subacute Cubital Tunnel Syndrome Because of an Intra-Cubital Tunnel Ganglion Cyst: A Case Report. *J Orthop Spine Trauma*. 2022;8:148-50.
4. Li P, Lou D, Lu H. The cubital tunnel syndrome caused by intra-neural ganglion cyst of the ulnar nerve at the elbow: a case report. *BMC Neurol*. 2018;18:217.
5. Papadopoulos DV, Kostas-Agnantis I, Kosmas D, et al. Ulnar intra-neural cysts as a cause of cubital tunnel syndrome: presentation of a case and review of the literature. *Eur J Orthop Surg Traumatol*. 2019;29:1559-1563.
6. Son B, Choi J, Ko H. Ulnar Neuropathy due to Intra-neural Ganglion Cyst of the Ulnar Nerve at the Elbow. *Indian J Neurosurg*. 2018;7:260-264.
7. Tong J, Xu B, Dong Z, et al. Cubital tunnel syndrome caused by ganglion cysts: a review of 59 cases. *Acta Neurochir (Wien)*. 2017;159:1265-1271.

8. Yalikun A, Yushan M, Hamiti Y, et al. Intraneural or extraneural ganglion cysts as a cause of cubital tunnel syndrome: A retrospective observational study. *Front Neurol.* 2022;13:921811.

9. Zacharia B, Poullose SP, Madhu M. Intraneural ganglion cyst of the ulnar nerve causing cubital tunnel syndrome masquerading a peripheral nerve abscess of a neuritic leprosy. *J Clin Orthop Trauma.* 2021;24:101692.